







Tinospora Cordifolia (Giloy)–Induced Liver Injury During the COVID-19 Pandemic—Multicenter Nationwide Study From India

Anand V. Kulkarni ¹, Pavan Hanchanale,² Vikash Prakash,³ Chetan Kalal,⁴ Mithun Sharma,⁵ Karan Kumar ⁶, Saptarshi Bishnu ⁷, Aditya V. Kulkarni ⁸, Lovkesh Anand,⁹ Ajay Kumar Patwa ¹⁰, Sandeep Kumber,¹¹ Sumeet Kainth,¹² Cyriac Abby Philips ¹³ and for the Liver Research Club India

Tinospora cordifolia (Giloy) is an herbal supplement commonly used in the Indian alternative medicine system Ayurveda. This herb has been promoted to the public in India as an immune booster to prevent novel coronavirus disease 2019. However, small reports have recently shown an association between Giloy use and the development of herb-induced liver injury (HILI) with autoimmune features in some patients. This large retrospective Indian multicenter study spanning 13 centers at nine locations was designed to identify features and outcomes of HILI temporally associated with Giloy use. Chemical and toxicological analyses of retrieved Giloy samples using state-of-the-art methods were also performed. We report 43 patients, of whom more than half were female, with a median time from initial Giloy consumption to symptom onset of 46 days. Patients presented with acute hepatitis, acute worsening of chronic liver disease (CLD, the most common clinical presentation), or acute liver failure. Causality assessment revealed probable liver injury in 67.4%. The most common autoantibody detected was anti-nuclear antibody. Liver biopsy in a subset revealed HILI associated with autoimmune features and hepatocyte and canalicular cholestasis and neutrophilic and eosinophilic infiltration. **Conclusion:** Giloy is associated with acute hepatitis with autoimmune features and can unmask autoimmune hepatitis (AIH) in people with silent AIH-related CLD. Further studies on the safety (and efficacy) of untested but heavily promoted herbals in alternative systems of medicine are an unmet need in the interests of public health and are especially important during this global health emergency. (*Hepatology Communications* 2022;6:1289-1300).

The novel severe acute respiratory syndrome coronavirus 2 (SARS-CoV-2)–related disease (COVID-19) was first identified in December 2019 and declared a pandemic on March 11, 2020. A total of 205,015,715 cases and 4,331,401 deaths due to COVID-19 had been reported worldwide as

of August 11, 2021.⁽¹⁾ During this pandemic, several paradigm shifts have occurred in relation to various preventive and therapeutic options, with vaccination against SARS-CoV-2 currently playing the central role in curbing infections and reducing mortality.⁽²⁾ Nonetheless, in developing countries such as India,

Abbreviations: AIH, autoimmune hepatitis; ALF, acute liver failure; ALT, alanine aminotransferase; ANA, anti-nuclear antibody; ASMA, anti-smooth muscle antibody; AST, aspartate aminotransferase; CI, confidence interval; CLD, chronic liver disease; COVID-19, coronavirus disease 2019; DILI, drug-induced liver injury; GC/MS-MS, gas chromatography–tandem mass spectrometry; HILI, herb-induced liver injury; IgG, immunoglobulin G; INR, international normalized ratio; IQR, interquartile range; IRB, institutional review board; LKM-1, anti-liver kidney microsome type 1; RUCAM, Roussel Uclaf Causality Assessment Model; SARS-CoV-2, severe acute respiratory syndrome coronavirus 2.

Received September 9, 2021; accepted January 8, 2022.

Additional Supporting Information may be found at onlinelibrary.wiley.com/doi/10.1002/hep4.1904/supinfo.

© 2022 The Authors. *Hepatology Communications* published by Wiley Periodicals LLC on behalf of American Association for the Study of Liver Diseases. This is an open access article under the terms of the [Creative Commons Attribution-NonCommercial-NoDerivs](https://creativecommons.org/licenses/by-nc-nd/4.0/) License, which permits use and distribution in any medium, provided the original work is properly cited, the use is non-commercial and no modifications or adaptations are made.

View this article online at [wileyonlinelibrary.com](https://onlinelibrary.wiley.com).

DOI 10.1002/hep4.1904

Potential conflict of interest: Nothing to report.

there is still widespread “non-evidence-based” use of investigational drugs (such as ivermectin), dietary supplements (such as vitamin C, D, and zinc), and complementary and alternative medicines, including those promoted for “prevention” of COVID-19 by the Ayurveda (various single or multiherbal preparations), Siddha (herbo-mineral preparations), and Homeopathy (Arsenicum album 30C) systems. Many of these drugs and dietary supplements are easily available over the counter and promoted and distributed by public authorities without strong evidence.⁽³⁾ Ayurvedic herbal medicines are well known to cause hepatotoxicity that can range from asymptomatic liver test abnormalities to acute liver failure (ALF) and acute-on-chronic liver failure (ACLF) in people with underlying liver disease.^(4,5)

Tinospora cordifolia, also known as the heart-leaved moonseed (or Giloy in Hindi and Guduchi in Sanskrit), is popularly marketed in India as an “immune-booster herbal supplement” with the “potential” to prevent COVID-19, despite a lack of strong clinical evidence for its use. Indeed, Giloy has been shown to have immune-stimulating properties with the potential to increase immunoglobulin G (IgG) in the serum in a small animal model.⁽⁶⁾ A recent paper describing 6 patients from a single center revealed that Giloy use could lead to acute hepatitis with autoimmune features or unmask an underlying autoimmune chronic liver disease (CLD).⁽⁷⁾

In this nationwide multicenter Giloy “immune-booster” liver injury study, we aimed to retrospectively

analyze the clinical presentation, outcomes, and histopathological features of patients presenting to multiple tertiary hospitals with a diagnosis of acute hepatitis associated with ingestion of pure Giloy or Giloy-based herbal preparations. Chemical and toxicology analyses of retrieved Giloy samples were also performed to explore potential mechanisms of potential herb-induced liver injury (HILI).

Patients and Methods

PATIENTS

This was a multicenter retrospective observational cohort study examining the clinical outcomes of Giloy-induced liver injury. The study was carried out by the Liver Research Club, India, a collaboration of hepatologists and gastroenterologists from 13 tertiary care hospitals in nine locations across India (North Zone: New Delhi, Punjab, and Uttar Pradesh; South Zone: Telangana, Karnataka, Tamil Nadu, and Kerala; East Zone: West Bengal; and West Zone: Maharashtra). We included all outpatients and inpatients > 18 years of age presenting with acute hepatitis associated with consumption of Giloy or a Giloy-containing herbal formulation. All patients were followed up for a minimum of 30 days and a maximum of 180 days, or until death or liver transplantation, whichever came first.

A thorough diagnostic workup was performed in all patients. Acute hepatitis was defined as aspartate

ARTICLE INFORMATION:

From the ¹Hepatology and Liver Transplantation, Asian Institute of Gastroenterology, Hyderabad, India; ²Department of Gastroenterology and Liver Transplantation, Jupiter Hospital, Pune, India; ³Department of Hepatology, D’CosMedics Clinic, Kolkata, India; ⁴Department of Hepatology and Liver Transplantation, Sir H. N. Reliance Foundation Hospital and Research Centre, Mumbai, India; ⁵Hepatology and Regenerative Medicine, Asian Institute of Gastroenterology, Hyderabad, India; ⁶Hepatology and Transplant Medicine, BGS Gleneagles Global Hospitals, Bengaluru, India; ⁷Department of Hepatology, Apollo Hospitals, Chennai, India; ⁸Gastroenterology and Hepatology, Antrang Hospital, Kohlapur, India; ⁹Department of Gastroenterology and Hepatology, Manipal Hospitals, Dwarka, New Delhi, India; ¹⁰Gastroenterology Unit, Department of Medicine, King George Medical University, Lucknow, India; ¹¹Department of Gastroenterology, KLE Suchirayu Hospital, Hubli, India; ¹²Gastroenterology and Hepatology, Ivy Hospital, Mohali, India; ¹³Clinical and Translational Hepatology, The Liver Institute, Center of Excellence in GI Sciences, Rajagiri Hospital, Aluva, India.

ADDRESS CORRESPONDENCE AND REPRINT REQUESTS TO:

Cyriac Abby Philips M.D., D.M.,
Clinical and Translational Hepatology, The Liver Institute,
Center of Excellence in GI Sciences
Ground Floor, Phase-II, Rajagiri Hospital, Chunangamvely,

Aluva
Kerala 683112, India.
E-mail: abbyphilips@theliverinst.in
Tel.: +91 484 290 5000

aminotransferase (AST) or alanine aminotransferase (ALT) levels > 3 times the upper limit of normal. Jaundice was defined as a bilirubin level > 3.5 mg/dL. Other well-recognized causes for liver injury were excluded based on laboratory tests, viral serologies (including nucleic acid test for SARS-CoV-2), diagnostic imaging, and the workup for Wilson disease. Autoimmune markers, including anti-nuclear antibody (ANA), anti-smooth muscle antibody (ASMA), anti-liver kidney microsome type 1 (LKM-1), and serum IgG levels, were measured in all patients. If patients consented, a liver biopsy was performed for histopathological evaluation. The Roussel Uclaf Causality Assessment Model (RUCAM) score and resulting causality grading was used to clinically diagnose HILI: 1-2, unlikely; 3-5, possible; 6-8, probable; and > 9, highly probable.⁽⁸⁾

Patients not completing the 1-month follow-up were excluded, and to allow accurate characterization of Giloy-induced liver injury, those with active alcohol consumption (patient-reported, confirmed with either immediate family member or a next of kin) in the preceding 3 months and those on concomitant, known hepatotoxic prescription drugs were also excluded, as were patients who were known to have autoimmune hepatitis (AIH)-related liver disease and who were in drug-free remission or on immunosuppression. The institutional review boards (IRBs) of the respective enrolled hospitals approved the study protocol and all centers complied with their local IRB requirements. The study was carried out in accordance with the Helsinki Declaration of 1975. Due to the retrospective analysis of existing clinical data, the requirement to obtain informed patient consent was waived by the respective IRBs.

STATISTICAL ANALYSIS

Statistical analyses were performed using MedCalc Statistical Software (Ostend, Belgium). Continuous variables are expressed as medians with 95% confidence intervals (CI) and interquartile ranges (IQRs), median with range, or mean and SDs, depending on the normality of the data. Categorical variables are summarized as counts and percentages.

ANALYSIS OF RETRIEVED SAMPLES

Heavy metal contamination, potential hepatotoxic volatile organic compounds, inorganic impurities,

insecticides, and pesticides were analyzed in herbal supplement samples retrieved from the patients, according to standard methodology as follows. Heavy metal concentration was determined by an inductively coupled plasma-atomic emission spectrometer (IRIS Intrepid II XSP Duo; Thermo Electron Corp., Munich, Germany) using chemical standards, reagents, and vials per the U.S. Environmental Protection Agency standards (methods 5021A, 8015, 8021, and 8260). Full-scan qualitative analyses was performed using gas chromatography coupled with tandem mass spectrometry (GC/MS-MS; Thermo Fisher Scientific, Waltham, MA). Pesticide residue analysis was performed using triple quadrupole GC/MS-MS (GC TRACE 1300 with TSQ_EVO 8000 MS).

Results

PATIENTS

Overall Patients

From April 2020 to July 2021, 49 patients with Giloy-induced liver injury were enrolled in the study. Of these, 6 patients were excluded (3 due to incomplete data, 2 who had no evidence of acute hepatitis, and 1 with more than a year of unconfirmed intermittent use of Giloy and suspicion of other hepatotoxic drug use); therefore, the final analysis included 43 patients with acute hepatitis which had no identifiable cause other than Giloy consumption. There was a higher number of females ($n = 23$ of 43, 53.5%), and the mean age the patients was 50.4 ± 13.8 years. Of the 43 patients, 13 had diabetes mellitus (30.2%), 10 had systemic hypertension (23.3%), 6 had hypothyroidism (14%), 3 had coronary heart disease (7%), and 20 (46.5%) were either overweight or obese. One patient had underlying chronic kidney disease, 1 had interstitial lung disease, and 1 had Sjogren's syndrome (2.3% for each). It was known that 7 patients (16.3%) had CLD (seronegative for AIH), and this disease was newly diagnosed during the evaluation of acute hepatitis among 17 (39.5%) patients. The HILI was managed in an inpatient setting for 26 patients (60.5%), while the symptoms of 17 (39.5%) were managed on an outpatient basis. Of the patients requiring inpatient management, 20 (46.5%) were hospitalized once, 5 (11.6%) twice, and 1 (2.3%) was hospitalized three times. At initial presentation, 7 patients (25.9%) were

admitted to the intensive care unit. In the whole cohort, the median follow-up period was 88 days (45-125) from the first consultation.

Biopsied Patients

There was a higher number of females ($n = 15$ of 22, 68.2%), and the patients had a mean age of 48.9 ± 9.95 years. Of the 22 patients, 7 had diabetes mellitus (31.8%), 2 each had systemic hypertension and coronary artery disease (9.1%), 5 had hypothyroidism (22.7%), and 14 (63.6%) were either overweight or obese. It was known that 4 patients (18.2%) had CLD (seronegative for AIH), while in 13 patients (59.1%) it was diagnosed during evaluation for acute hepatitis presentation. The HILI was managed in an inpatient setting for 17 patients (77.3%). Of the patients requiring inpatient management during the course of illness, 14 (63.6%) were hospitalized once, 3 (13.6%) twice, and 1 (4.5%) was hospitalized three times. At initial presentation, 12 patients (66.7%) were admitted to the intensive care unit. In the biopsy cohort, the median follow-up period was 97 days (30-166) from the first consultation.

CLINICAL PRESENTATION AND INVESTIGATIONAL DETAILS

Overall Patients

Patients with Giloy-induced liver injury presented with acute hepatitis ($n = 19$, 44.2%), acute worsening of CLD ($n = 22$, 51.1%), or ALF ($n = 2$, 4.7%). Giloy-induced liver injury was "possible" (score 3-5) in 14 patients (32.6%) and "probable" (score 6-8) in 29 patients (67.4%) according to the RUCAM scores. Overall, at presentation, clinical jaundice was seen in 33 (76.7%), cholestatic symptoms in 20 (46.5%), ascites in 22 (51.2%), and overt hepatic encephalopathy in 7 (16.3%) patients. During the follow-up period, new or worsening clinical events were seen in 15 patients: ascites in 6 (14%), hepatic encephalopathy in 5 (11.6%), infection or sepsis in 2 (4.7%), and sepsis with a portal hypertensive event in 2 (4.7%). The median total bilirubin at presentation was 11.7 (range 0.5-46.6) mg/dL, AST = 305 (85-1,637) IU/L, ALT = 281 (56-1,269) IU/L, total protein = 6.6 (4.3-8.0) g/dL, serum albumin = 3.5 (2.1-4.6) g/dL, and international normalized ratio (INR) = 1.53 (0.8-6.0). ANA was detected in 18 (41.9%), ASMA in 5 (11.6%), and anti-LKM-1 in 3 (7%) patients with

Giloy-related acute hepatitis. The mean IgG level was $1,850.9 \pm 870.2$ (range 888-5,583) g/L. All investigative results including details of antibody titers are given in Table 1. On subgroup analysis, no significant differences were noted between possible and probable groups with respect to demographics, pertinent clinical, investigational and histopathological presentations, as well as outcomes, except for hemoglobin level at baseline (Supporting Table S1). Four patients (9.3%, all with acute worsening of CLD) died (at 26, 32, 45, and 60 days from clinical presentation), and 2 patients (4.7%, 1 with ALF, and with 1 acute worsening of CLD) underwent liver transplantation (at 58 and 62 days from clinical presentation). The rest ($n = 37$, 86%) recovered fully or had stable liver functions on treatment at 6 months from clinical presentation.

Biopsied Patients

Patients with Giloy-induced liver injury presented with acute hepatitis ($n = 7$, 31.8%), acute worsening of CLD ($n = 13$, 59.1%), or ALF ($n = 2$, 9.1%). Giloy-induced liver injury was "possible" (score 3-5) in 9 patients (40.9%) and "probable" (score 6-8) in 13 patients (59.1%) according to the RUCAM scores. Clinical jaundice was seen in 19 (86.4%), cholestatic symptoms in 9 (40.9%), ascites in 13 (59.1%), and overt hepatic encephalopathy in 7 (31.8%) patients. During the follow-up period, new or worsening clinical events were seen in 15 patients: ascites in 2 (9.1%), hepatic encephalopathy in 3 (13.6%), and sepsis with a portal hypertensive event in 1 (4.5%). The median total bilirubin at presentation was 13.8 (range 0.6-46.6) mg/dL, AST = 263 (85-1,637) IU/L, ALT = 229 (87-1,269) IU/L, serum albumin = 3 (2.1-4.3) g/dL, globulin = 3.4 (1.9-4.6) g/dL, and INR = 1.64 (0.8-4.7). ANA was detected in 14 (63.6%), ASMA in 2 (9.1%), and anti-LKM-1 in 1 (4.5%) patients with Giloy-related acute hepatitis. The ANA titer was 1:40 in 3 (21.4%), 1:80 in 4 (28.6%), 1:100 in 5 (35.7%), and 1:320 and 1:3,200 in 1 each (7.1%). The mean IgG level was $2,040.3 \pm 1,024.8$ (range 989-5,583) g/L. All investigative results are found in Supporting Table S2. Two patients (9.1%, all with acute worsening of CLD) died, and 1 patient with ALF (4.5%) underwent liver transplantation. The rest ($n = 19$, 86.4%) recovered fully or had stable liver functions on treatment at 6 months from clinical presentation. According to the International Autoimmune Hepatitis

TABLE 1. DETAILS OF PATIENTS ENROLLED INTO THE GILOY-INDUCED LIVER INJURY STUDY

Variable	Minimum	Maximum	Mean	Median	95% CI	SD	25-75 P
Age (years)	18	80	50.4	54	47-57	13.8	43.0- 60.7
Hemoglobin (g/dL)	8.3	15.7	11.5	11.3	10.8-12.0	1.6	10.4-12.5
Total white blood cell counts ($\times 10^3/\mu\text{L}$)	3.1	27.5	8.3	6.8	6.2-8.5	4.8	5.3-9.7
Platelet counts ($\times 10^6/\mu\text{L}$)	0.56	3.4	1.8	1.7	1.6-2.0	0.6	1.4-2.3
Total bilirubin (mg/dL)	0.5	46.6	13.6	11.7	8.1-18.0	11.1	3.4-19.1
Direct bilirubin (mg/dL)	0.1	31.5	8.6	7.3	5.1-11.9	6.8	2.6- 13.8
AST (IU/L)	85	1,637	429.7	305	226.3-404.0	360.4	196.7-506.5
ALT (IU/L)	56	1,269	393.8	281	187.2-391.7	333.6	152.2-481.5
Alkaline phosphatase (IU/L)	61	1,605	215.4	140	125.2-186.5	247.2	108.3-225
Gamma glutamyltransferase (IU/L)*	29	2,816	184.3	98	81.0-106.7	419.9	68.5-174
Total protein (g/dL)	4.3	8	6.6	6.6	6.4-6.9	0.7	6.3-7.3
Albumin (g/dL)	2.1	4.6	3.3	3.5	2.9-3.7	0.7	2.8-3.8
Globulin (g/dL)	1.4	4.6	3.3	3.4	3.1-3.5	0.7	2.9-3.8
Blood urea (mg/dL)	12	151	34.5	23	20.6-31.4	29.6	18.0-34.7
Creatinine (mg/dL)	0.4	7.3	1.1	0.8	0.7-0.9	1.1	0.7-1.1
Sodium (mEq/L)	118	145	134.9	136	133.6-137.3	5.1	131.0-138.7
Potassium (mEq/L)	2.2	5.6	4.1	4.1	3.9-4.3	0.6	3.8-4.5
INR	0.8	6	1.9	1.5	1.2-1.9	1.1	1.1-2.3
Total IgG (g/L)	888	5,583	1,850.9	1,642	1,387.5-1,906.2	870.2	1,296.7-2,161.3
Amount of Giloy consumed per day (mL)	15	90	40.7	40	30.0-50.1	19.7	25-60
Development of symptoms from start of Giloy-based formulation (days)	2	365	80.5	46	29.2-88.7	89.2	21-106
Total number of days Giloy consumed	5	362	81.2	42	27.6-84.7	93.1	21-92
Total follow-up days from first consultation	30	180	90.6	88	—	51.3	45.0-125.5
Details on auto-antibodies (n = 43)	ANA positive: n = 18, 41.9%		ASMA positive: n = 5 (11.6%)		Anti-LKM-1 positive: n = 3 (7%)		
	Antibody titers:		Antibody titers:		Antibody titers:		
	1:100 (n = 5, 27.8%),		1:40 (n = 4, 80%)		1:40 (n = 3, 100%)		
	1:40 and 1:80 (n = 4 each, 22.2% each)		1:80 (n = 1, 20%)				
	1:160 and 1:320 (n = 2 each, 11.2% each)						
	1:3,200 (n = 1, 5.6%)						

*n = 32; rest n = 43.

25-75 P means between 25th and 75th percentiles.

Group's revised original score (pretreatment) for AIH, 18 patients (81.8%) had no or possible (score < 10), while 4 (18.2%) had probable (score 10-15) autoimmune hepatitis and none had definite AIH.

All patients with biopsy features of HILI and auto-immune features and those with hepatitis associated with jaundice and autoantibody positivity were treated with corticosteroids; all others received symptomatic and supportive care in the form of weight-based oral ursodeoxycholic acid, N-acetyl cysteine, and control of the underlying metabolic syndrome. In patients with features of chronicity on imaging or biopsy, low-dose immunosuppressive maintenance with corticosteroids

and azathioprine or mycophenolate mofetil in those not tolerating azathioprine were continued after remission. In the others, steroids were tapered and stopped after symptoms completely resolved and liver tests normalized.

GILOY USE AND ASSOCIATED DETAILS

Overall Patients

The patients ingested Giloy either in pure/extracted form (n = 25, 58.1%) or as part of a multiherbal formulation (n = 18, 41.9%). Most (n = 36,

83.7%) consumed it in the form of decoctions made from extracts of freshly sourced or powdered formulations. It was consumed in the form of tablets alone by 5 patients (11.6%) and in the form of both tablets and decoctions by 2 patients (4.7%). The formulations were pure and sourced from nearby pharmacies (26 patients, 60.5%), naturally sourced and homemade (12 patients, 27.9%), or manufactured by multinational Ayurvedic pharmaceutical companies (5 patients, 11.6%) (Fig. 1).

During the period of Giloy consumption, 5 patients (11.6%) also intermittently consumed other herbal formulations. These included aloe vera and Indian gooseberry (Amla) decoction; the classical Ayurvedic formulation *Arjunarishta* (containing bark of *Terminalia arjuna*, flowers of *Woodfordia fruticosa* and *Madhuca Indica*, and fruit of *Vitis vinifera*); a proprietary drug (containing *Achillea Millefolium*, *Berberis Aristata*, *Boerhaavia Diffusa*, *Capparis Sepiaria*, *Cassia Occidentalis*, *Embllica Officinalis*, *Fumaria Officinalis*, *Mandur Bhasma*, *Plumbago Zeylanica*, *Solanum Nigrum*, *Solanum Xanthocarpum*, *Tamarix Gallica*, *Terminalia Arjuna*, *Terminalia Chebula*, and Giloy as active ingredients); turmeric (*Curcuma longa*) and tulsi (*Ocimum sanctum* or holy basil); and pepper, ginger, and clove extracts in 1 patient (2.3%) each. The median total duration of Giloy consumption was 42 days (95% CI: 27.7-84.7; IQR: 21-92), and the median time from the start of Giloy ingestion to symptom development was 46 (95% CI: 29.2-88.7; IQR: 21-106) days. The amount of Giloy consumed was variable with unavailable

details in 11 patients (25.6%). In the remaining 32 patients, the mean daily intake was quantified as 40.8 ± 19.7 mL.

LIVER HISTOPATHOLOGY OF GILOY-INDUCED LIVER INJURY

Liver biopsies were performed in 22 patients (51.2%). Of these biopsies, 12 (54.5%) were trans-jugular, 8 (36.4%) were percutaneous, and 2 (9.1%) were endoscopic ultrasound-guided. Hepatocellular necrosis was seen in 14 (63.6%) patients; of these, 6 (42.9%) had spotty or focal necrosis, 5 (35.7%) had bridging or confluent necrosis, and 3 (21.4%) had submassive or massive necrosis. The most common inflammation type (11 patients, 50%) was mixed (neutrophilic and lymphoplasmacytic), and the most common inflammation pattern (12 patients, 54.5%) was portal-based. Interface hepatitis was notable in 17 patients (77.3%) and graded as severe in 4 of the 17 patients (23.5%). Rosetting of hepatocytes was seen in 9 patients (40.9%). Cholestatic changes on liver histology were seen in 17 (77.3%) patients, of whom 6 (35.3%) had both intracanalicular and hepatocellular patterns of cholestasis. Eosinophils on liver biopsy were notable in 15 (68.2%) patients, and 6 of these (40%) had moderate grade infiltration. Hepatocyte steatosis was seen in 8 patients (36.4%) and ballooning in 9 patients (40.9%). Fibrosis was notable in 17 liver biopsy specimens (77.3%), classified as grade 2 (8 patients, 47.1%), 3 (4 patients, 23.5%), or 4 (2 patients, 11.8%) (Fig. 2).



FIG. 1. Some of the Giloy-based formulations as well as raw Giloy plant retrieved from patients with HILL.

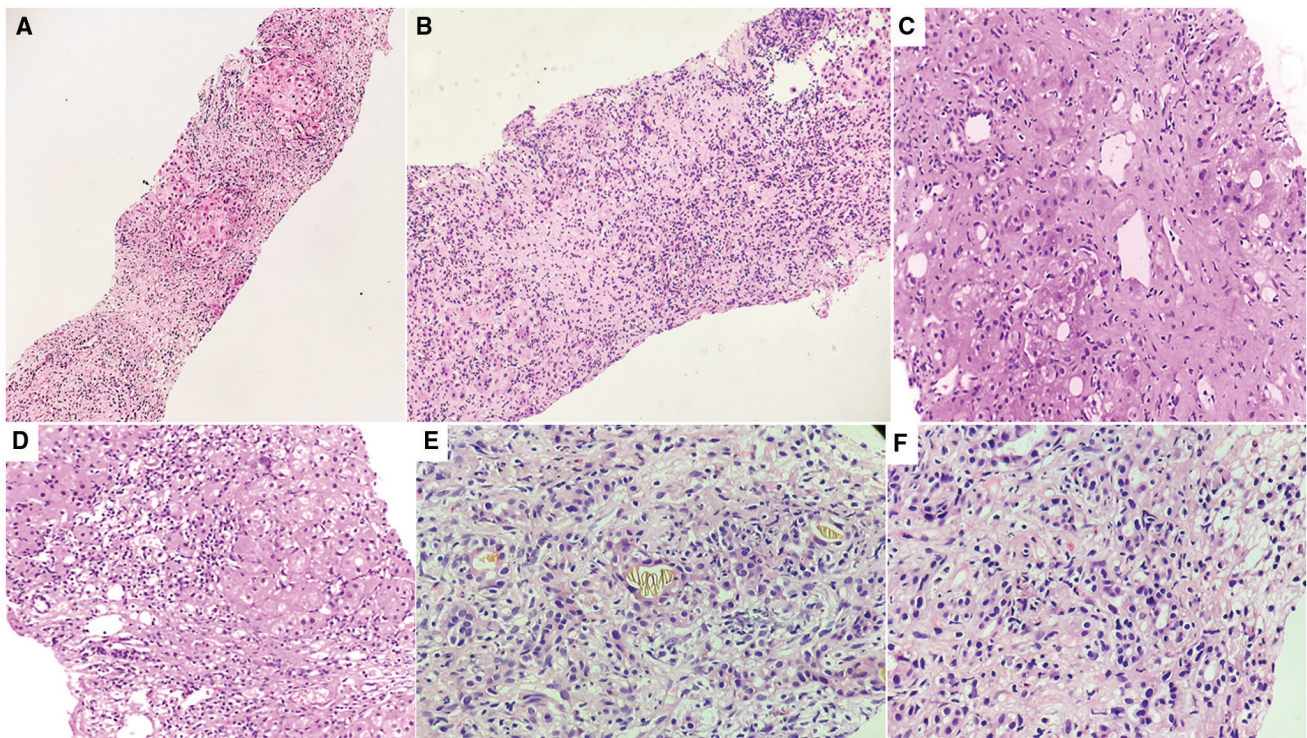


FIG. 2. Liver histopathological features of patients with Giloy-induced liver injury. (A) Mixed inflammatory reaction in portal and lobular regions in patient with underlying chronic liver disease (hematoxylin and eosin [H&E] stain, $\times 10$), (B) Confluent necrosis associated with neutrophilic and lymphoplasmacytic inflammation (H&E stain, $\times 40$). (C) Ballooning of hepatocytes with perivenular necrosis (H&E stain, $\times 100$). (D) Moderate interface hepatitis with mixed inflammatory infiltrate (H&E stain, $\times 100$). (E) Canalicular bile plugs (H&E stain, $\times 200$). (F) Eosinophilic infiltration amidst neutrophils and plasma cell rich inflammation (H&E stain, $\times 200$).

ANALYSIS OF RETRIEVED SAMPLES

A total of six different types of Giloy formulations retrieved from the patients underwent chemical and toxicology analysis (Table 2). These samples included fresh Giloy plant retrieved by the patient, private pharmaceutical manufactured Giloy decoction, locally available and publicly sponsored State pharmacy-manufactured Giloy powder, and pure and multiherbal Giloy tablets manufactured by private Ayurvedic companies. Heavy metal contamination with mercury, arsenic, and lead above prescribed limits were notable in two samples. Gas chromatography analysis revealed multiple phytochemicals with potential immunomodulatory effects and hepatotoxic potential,⁽⁹⁾ such as sesquiterpenes, diterpenoids, glycosides, and phytosterols. Some samples also showed industrial solvents, presumably introduced inadvertently during the manufacturing process.

Discussion

Tinospora cordifolia or Giloy, advertised as an “immune-booster” during the COVID-19 pandemic, is considered to have various medicinal properties despite the absence of methodically performed clinical studies. It is believed to have hypoglycemic, diuretic, anti-inflammatory, anti-oxidant, analgesic, antimalarial, hepatoprotective, immunomodulatory, and anti-neoplastic attributes. Studies on Giloy are mostly preclinical with no strong evidence for use in humans to prevent or treat any disease.⁽¹⁰⁾ Our study is the largest published series of cases of Giloy-induced acute hepatitis, describing pooled data analysis of 43 patients from multiple tertiary centers across India.

Our findings support the previously described clinical, investigational, and histological features associated with Giloy-induced liver injury. In our series, close to one-third of patients were diabetic, nearly half were overweight or obese, three-fifths required

TABLE 2. CHEMICAL AND TOXICOLOGY ANALYSIS OF RETRIEVED GILOY AND GILOY-BASED FORMULATIONS

Product	Heavy Metals (mg/kg)				Organic and inorganic compounds detected on complete GC/MS-MS scan
	Arsenic	Lead	Mercury	Cadmium	
Pure Giloy herb (source: Kerala)	0.62	9.43	0.04	BDL	Carpylic acid, Estafiatin, Phytol, Methyl stearate, Phthalic acid, Columbin, Fenretinide, Squalene, α -Tocopherol, Sitosterol, Lupeol, Decanoic acid
Giloy herb decoction (manufactured by multinational company)	1.2	BDL	BDL	BDL	Dihydroxanthin, Shyobunol, Nootkaton epoxide, Estafiatin, Estratrienol, Ingol acetate, Dihydroxy cholecalciferol, Dihydrogathic acid, Methyl octadecenoate, Propanoic acid, Columbin, Palmifin, Hydroxy spirosteneone
Local pharmacy-made Giloy herb powder	BDL	1.88	BDL	BDL	Methoxy phenol, Butyl phenol, Lithium chloride, Cobalt hexahydrate, Manganese tetrahydrate, Calcium chloride, Tachyhydrite
State pharmacy-made Giloy powder	3.13	13.58	5.31	1.02	Methoxy phenol, Turmerone, Methyl eugenol, Curcumene, Shyobunol, Asarone, Methyl palmitic acid, Amyrin, Lupeol, Oleanol acetate, Nitrosoamine, Amyl nitrate, Licarin A, Licarin B, Capesterol, Stigmasterol, Columbin, α -Tocopherol
Pure Giloy tablets (manufactured by multinational company)	BDL	BDL	1.77	0.09	Methoxy phenol, Decanoic acid, Asarone, Turmerone, Myristic acid, Lauric anhydride, Palmitic acid, methyl ester, Estafiatin, Columbin, Campesterol, Stigmasterol, Sarsasapogenin, Lupeolo-sitosterol, Amyrin, Sitostenone
Multitherbal formulation with Giloy as main component (proprietary drug by Ayurveda company)	BDL	1.74	BDL	0.14	Sorbic acid, Maltol, Vanillin lactoside, Ingol acetate, Estratrienol, Dihydroxanthin, Nootkaton epoxide, Palmitic acid, Estafiatin, Methyl ester-linoleic acid, Mono-olein, Columbin, Lycocoxanthin, Supraene, Campesterol, Stigmasterol, Sitosterol, Olecanone, Lupenone
					Nitrosomethane, Methoxy phenol, Butyl phenol, Paromomycin, Benzophenone, Chromium hydrate, Evansite, Chabasite
					Tropine, Ascaridole epoxide, Methoxy phenol, Butyl phenol
					Eugenol, Linolenin, Vanillin, Tyrosol, Galactidose, Butylhydroxyanisole, Ingol acetate, Isoaramadrene epoxide, Longipinocarveol, Dimethoxy phenyl acetate, Dihydroxanthin, Nootkaton epoxide, Estratrienol, Methyl ester-linoleic acid, Phytol, Methyl stearate, Thunbergol, Columbin, Squalene, α 1-Tocospiro B, α 1-Tocospiro A, Trimesityl borane, Rhodopin, Norleanadiene, Tocopherol, Norursadiene, Cholestenol, Campesterol, Astaxanthin, Stigmasterol, Sitosterol, α 1-Amyrin, Lupeol

Abbreviation: BDL, below detection limit.

in-hospital management, and a quarter required intensive care. Most patients had self-medicated pure Giloy-based formulations in the form of decoctions purchased locally, and the median duration of Giloy consumption was 42 days. The median time from first Giloy ingestion to development of symptoms was 46 days, and the patients had a mean intake of 40.8 mL per day. The most common clinical presentation was acute worsening of CLD followed by acute hepatitis, and the most common auto-antibody was ANA. Close to 10% of the patients in this series died within 2 months of presentation, and nearly 5% required liver transplantation within 3 months. Liver histology was suggestive of HILI with autoimmune features, not classical AIH, with additional atypical features in most of the patients who underwent biopsy such as hepatocyte and canalicular cholestasis and neutrophilic and eosinophilic infiltration. Analysis of retrieved Giloy samples did not reveal any competing hepatotoxic agents.

Previous phytochemical analysis of Giloy has identified various plant-derived chemicals such as alkaloids, steroids, diterpenoid lactones, and glycosides. Different extracts possess different pharmacological activities, including immunotherapeutic properties. The aqueous extract of the stem is reported to contain immunologically active arabinogalactan polysaccharides with significant polyclonal B-cell activation properties.⁽¹¹⁾ B cells play an active role in the pathogenesis of AIH, and B-cell depletion is beneficial for AIH remission in preclinical studies,⁽¹²⁾ suggesting a potential mechanism by which Giloy phytochemicals could unmask AIH in patients with quiescent chronic AIH. Another study demonstrated that the aqueous extract of Giloy stem ameliorated immunosuppressive properties of splenic macrophages isolated from carbon tetrachloride-induced immunosuppressive mice, demonstrating the immunostimulant and macrophage activation properties associated with Giloy phytochemicals.⁽¹³⁾ Macrophage activation markers were elevated in one study of AIH and normalized by successful treatment in complete responders in the acute phase, demonstrating that macrophage activation in AIH parallels disease activity, severity, and treatment response, and suggesting a role for macrophage activation in AIH.⁽¹⁴⁾ Thus, there is preclinical evidence that immunostimulant properties of *Tinospora* species as well as Giloy-related bioactive compounds on macrophage function could lead to an herbal-induced

immune modulatory phenomenon and cause flares of silent chronic AIH, as noted in our group of patients.⁽¹⁵⁾

Immune-associated liver injuries attributable to Ayurvedic herbal drugs were previously described in a large group of patients.⁽¹⁶⁾ In this study, Giloy was a component in eight different herbal formulations retrieved for analysis. Autoantibodies were found in 29.6% of patients, with ANA in 25.9%, LKM-1 antibodies in 7.4%, and anti-mitochondrial antibodies in 3.7%. Chronic hepatitis was the most common finding, with interface hepatitis in 70.4%. In a similar vein, a series of 6 patients with Giloy-induced hepatitis demonstrated an autoimmune pattern of DILI on biopsy, and 4 of 6 had an underlying silent CLD of possible autoimmune etiology associated with other autoimmune-related diseases such as hypothyroidism and diabetes.⁽⁷⁾ The authors suggested that Giloy use in predisposed patients could induce hepatitis with autoimmune features or unmask an underlying autoimmune CLD due to its aforementioned immunostimulant mechanisms, which may also result in significant liver toxicity and lead to severe acute hepatitis and to ACLF or ALF, which was also apparent in our series of patients.^(6,7)

There are multiple clinical scenarios involving both DILI/HILI and AIH. These include drug-induced AIH, a second episode of DILI mimicking a course of relapsing AIH, chronic DILI mimicking AIH, DILI or HILI with AIH characteristics, and immune-mediated DILI/HILI.⁽¹⁷⁾ In our study and that by Nagral et al.,⁽⁷⁾ Giloy-related hepatitis appears to be associated both with herb-induced AIH or HILI with AIH features and a flare of chronic AIH due to Giloy's immune-potentiating properties. Chronic AIH triggered by the use of herbals has been documented for the Japanese multiherbal Kampo formulation Dai-Saiko-to⁽¹⁸⁾; the traditional Chinese medicine, Ma huang, an ephedrine-type alkaloid often used for weight loss resulting in fulminant exacerbation of subclinical AIH⁽¹⁹⁾; and recently, ingestion of Xiang-tian-Guo (*Swietenia macrophylla* seeds) ingestion for 6 months resulting in HILI with AIH features on biopsy.⁽²⁰⁾ Another study showed that immunostimulatory herbal supplements containing Echinacea and algae might exacerbate pre-existing autoimmune disease or precipitate autoimmune disease in persons genetically predisposed to such disorders.⁽²¹⁾

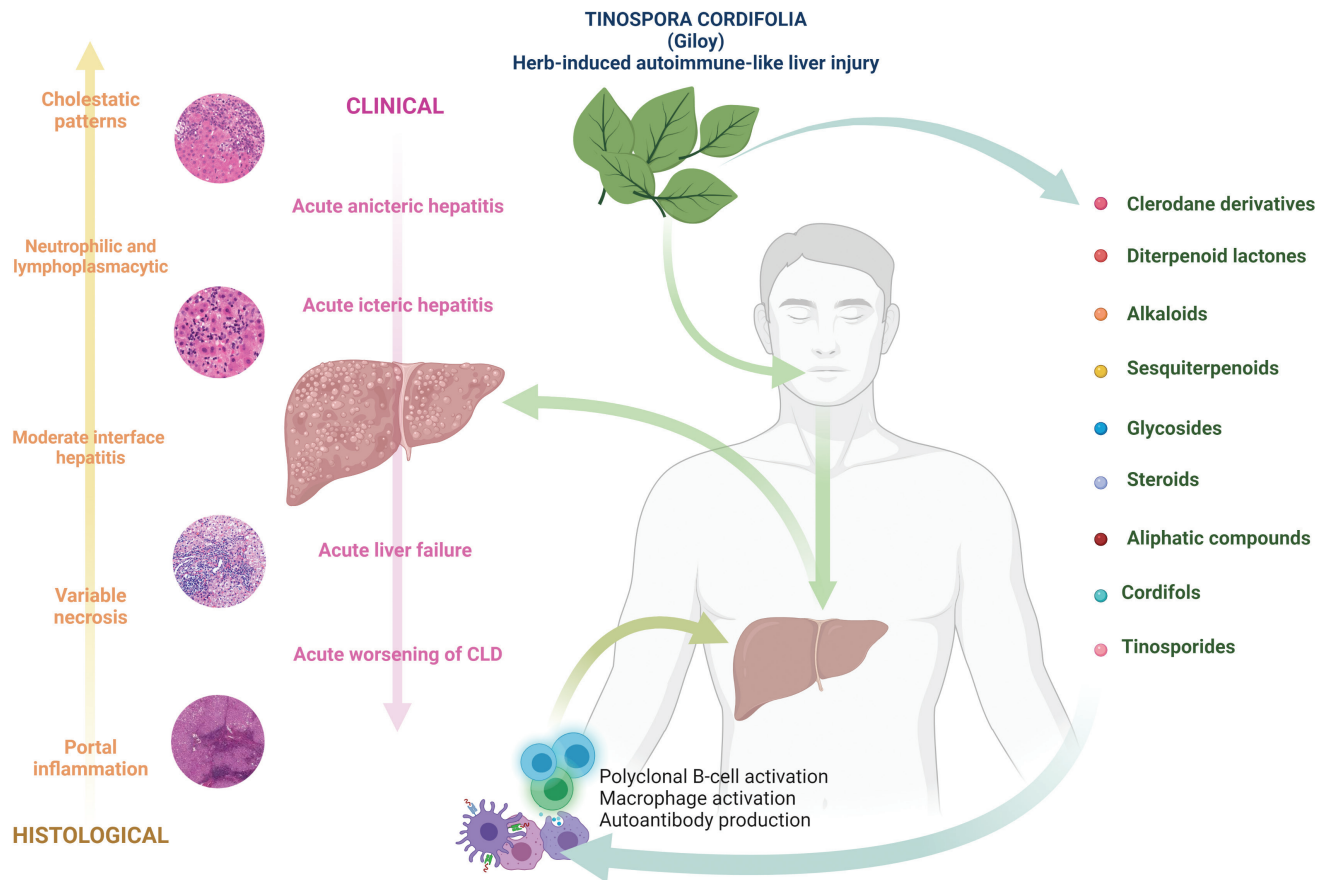


FIG. 3. Infographic summary.

HILI with AIH features, herb-induced AIH, and flares of chronic AIH all lead to self-limiting acute hepatitis, a severe acute liver injury requiring treatment. ALF and acute worsening of CLD were also notable.

Similar findings are striking with Ayurvedic herbal Giloy-induced liver injury. There was a wide range of time to disease onset (2-365 days) in our patients with Giloy-induced hepatitis and a plethora of clinical presentations that could be dependent on dose, frequency, duration, type of formulation (whole plant versus parts), final concentration of bioactive compounds, presence of other herbal components, and herb-herb interactions that ultimately dysregulate immune homeostasis and promote liver injury in predisposed persons.

Our study is the largest multicenter series on Giloy-induced hepatitis with autoimmune features, but has several limitations. It was a retrospective study, which means that some clinical and investigational data are incomplete. Furthermore, the

treatments were heterogeneous, which could have affected outcomes. However, our data-collection methods were designed to include the minimal diagnostic elements required to substantiate the diagnosis of the DILI/HILI.⁽²²⁾ All patients had negative hepatitis C virus antibodies, but a hepatitis C RNA-polymerase chain reaction test was not performed in all. However, clinical suspicion for viral hepatitis was very low. We were not able to clarify liver toxicity due to mislabeled and undisclosed ingredients in multiherbal products containing Giloy. The exact component(s) that caused liver injury with multiherbal products containing Giloy use was unknown. However, we analyzed raw herb and drug samples retrieved from 6 patients, and were able to reveal the differential (qualitative) presence of potentially hepatotoxic phytochemicals such as terpenoids and plant alkaloids and to rule out other known hepatotoxic components such as impurities and contaminants. A direct dose measurement of Giloy or Giloy-based

formulation taken by the patients in this study could not be recorded, as many samples were unlabeled and raw herbs were used to make extracts at home. The recorded dose for each patient was therefore an estimate with the possibility of recall bias, and a realistic toxic dose calculation could not be performed.

Although the exact amount of consumed Giloy associated with liver injury could not be precisely elucidated from this retrospective report, it is still important to bring attention to the potential for HILI from this herbal supplement—regardless of whether a precise causative amount was determined. It is pertinent to note that several of the supplements intermittently consumed during the time period of Giloy consumption such as aloe vera, Indian gooseberry, and turmeric were also potentially (synergistically) hepatotoxic.

Only half of the patients consented to liver biopsy, so histological assessment for classical AIH was not possible in every patient. However, most of the available biopsy samples did not display histopathological features of classical AIH, and the pretreatment revised AIH scores among biopsied patients were not suggestive of definite AIH in any. Atypical features such as the portal-based, mixed pattern of inflammation associated with cholestasis were predominant, demonstrating a high probability of herb-induced hepatitis with autoimmune features due to Giloy use. The RUCAM scores indicated that patients were in the possible–probable range for HILI. Rechallenge was not considered due to ethical considerations, especially because many patients developed features of severe injury on first exposure, which improved after herb withdrawal.⁽²³⁾ Serologies for rare viral infections such as cytomegalovirus and Epstein-Barr virus were not performed in some patients. However, none of these patients had risk factors or clinical features strongly associated with acute atypical viral infections.

One can argue that the samples might have been contaminated with *Tinospora crispa*, a related species with known hepatotoxic potential due to the presence of clerodane furano-diterpenoids. However, *Tinospora cordifolia* also contains clerodane furano-diterpenoids with the potential to harm.⁽²⁴⁾

HILI mechanisms can vary, from direct herb hepatotoxicity to liver injury from secondary metabolites or immune-mediated phenomenon. In the case of multiherbal formulations, pathomechanisms can play a role in promoting liver injury. Based on previously published findings, direct cellular and humoral

immunomodulatory mechanisms of the herb-related metabolites in Giloy could cause HILI with autoimmune features and could also unmask AIH in those with quiescent disease. The HILI due to Giloy could be an acute idiosyncratic injury (Fig. 3).

HILI due to Giloy is an important cause of autoantibody-mediated acute hepatocellular jaundice in the absence of other competing causes. Positive autoimmune markers in acute (nonviral) hepatitis may indicate that AIH has been triggered or unmasked, for which active reasons must be sought, and this should include recent or long-term exposure to herbals containing Giloy. Rigorous studies on the safety and efficacy of commonly used herbal formulations in India remain an unmet need. The fact that “herbal” and “natural” do not mean “safe” is illustrated yet again in this series of patients, and public health authorities must take the necessary steps not to promote herbal formulations based on traditional beliefs but rather to educate the public regarding the potential liver toxicity of untested herbal products.

REFERENCES

- 1) <https://www.worldometers.info/coronavirus>. [Accessed August 11, 2021]
- 2) Creech CB, Walker SC, Samuels RJ. SARS-CoV-2 vaccines. *JAMA* 2021;325:1318-1320.
- 3) Paudyal V, Sun S, Hussain R, Abutaleb MH, Hedima EW. Complementary and alternative medicines use in COVID-19: a global perspective on practice, policy and research. *Res Social Adm Pharm* 2021 May 13. <https://doi.org/10.1016/j.sapharm.2021.05.004>. [Epub ahead of print]
- 4) Philips CA, Ahamed R, Rajesh S, George T, Mohanan M, Augustine P. Comprehensive review of hepatotoxicity associated with traditional Indian Ayurvedic herbs. *World J Hepatol* 2020;12:574-595.
- 5) Philips CA, Paramaguru R, Augustine P, Rajesh S, Ahamed R, George T, et al. A single-center experience on outcomes of complementary and alternative medicine use among patients with cirrhosis. *Hepatol Commun* 2019;3:1001-1012.
- 6) Kafil A, Sharma S. Immunopotentiating compounds from *Tinospora cordifolia*. *J Ethnopharmacol* 1997;58:89-95.
- 7) Nagral A, Adhyaru K, Rudra OS, Gharat A, Bhandare S. Herbal immune booster-induced liver injury in the COVID-19 pandemic—a case series. *J Clin Exp Hepatol*. 2021;11:732-738.
- 8) Hayashi PH. Overview of causality assessment in drug-induced liver injury [published correction appears in *Clin Liver Dis* 2019;13:184]. *Clin Liver Dis* 2017;9:29-33.
- 9) Quan NV, Dang Xuan T, Teschke R. Potential hepatotoxins found in herbal medicinal products: a systematic review. *Int J Mol Sci* 2020;21:5011.
- 10) Saha S, Ghosh S. *Tinospora cordifolia*: one plant, many roles. *Anc Sci Life* 2012;31:151-159.
- 11) Chintalwar G, Jain A, Sipahimalani A, Banerji A, Sumariwalla P, Ramakrishnan R, et al. An immunologically active arabinogalactan from *Tinospora cordifolia*. *Phytochemistry* 1999;52:1089-1093.

- 12) Béland K, Marceau G, Labardy A, Bourbonnais S, Alvarez F. Depletion of B cells induces remission of autoimmune hepatitis in mice through reduced antigen presentation and help to T cells. *Hepatology* 2015;62:1511-1523.
- 13) Chakraborty B, Sengupta M. Supporting the immune system through functional modulation of carbon tetrachloride intoxicated splenic macrophages by administering *Tinospora cordifolia*. *J Appl Pharm Sci* 2012;2:117.
- 14) Grønbaek H, Kreutzfeldt M, Kazankov K, Jessen N, Sandahl T, Hamilton-Dutoit S, et al. Single-centre experience of the macrophage activation marker soluble (s)CD163—associations with disease activity and treatment response in patients with autoimmune hepatitis. *Aliment Pharmacol Ther* 2016;44:1062-1070.
- 15) Haque MA, Jantan I, Abbas Bukhari SN. *Tinospora* species: an overview of their modulating effects on the immune system. *J Ethnopharmacol* 2017;207:67-85.
- 16) Philips CA, Paramaguru R, Joy AK, Antony KL, Augustine P. Clinical outcomes, histopathological patterns, and chemical analysis of Ayurveda and herbal medicine associated with severe liver injury—a single-center experience from southern India. *Indian J Gastroenterol* 2018;37:9-17.
- 17) Sebode M, Schulz L, Lohse AW. “Autoimmune(-like)” drug and herb induced liver injury: new insights into molecular pathogenesis. *Int J Mol Sci* 2017;18:1954.
- 18) Kamiyama T, Nouchi T, Kojima S, Murata N, Ikeda T, Sato C. Autoimmune hepatitis triggered by administration of an herbal medicine. *Am J Gastroenterol* 1997;92:703-704.
- 19) Borum ML. Fulminant exacerbation of autoimmune hepatitis after the use of ma huang. *Am J Gastroenterol* 2001;96:1654-1655.
- 20) Shao YM, Zhang Y, Yin X, Qin TT, Jin QL, Wen XY. Herb-induced autoimmune-like hepatitis associated with Xiang-tian-guo (*Swietenia macrophylla* seeds): a case report and literature review. *Medicine* 2021;100:e24045.
- 21) Lee AN, Werth VP. Activation of autoimmunity following use of immunostimulatory herbal supplements. *Arch Dermatol* 2004;140:723-727.
- 22) Agarwal VK, McHutchison JG, Hoofnagle JH. Drug-Induced Liver Injury Network. Important elements for the diagnosis of drug-induced liver injury. *Clin Gastroenterol Hepatol* 2010;8:463-470.
- 23) Hunt CM, Papay JI, Stanulovic V, Regev A. Drug rechallenge following drug-induced liver injury. *Hepatology* 2017;66:646-654.
- 24) Philips CA, Abraham L. *Tinospora cordifolia* (Giloy) and autoimmune-like liver injury—a classic case of Primum Non Nocere, “First, Do No Harm.” *J Clin Exp Hepatol* 2022;12:245-246.

Supporting Information

Additional Supporting Information may be found at onlinelibrary.wiley.com/doi/10.1002/hep4.1904/supinfo.